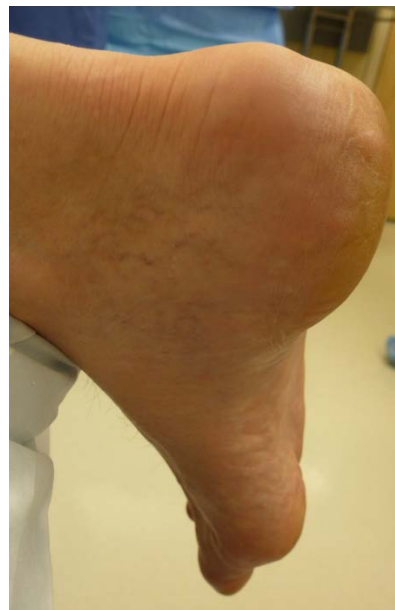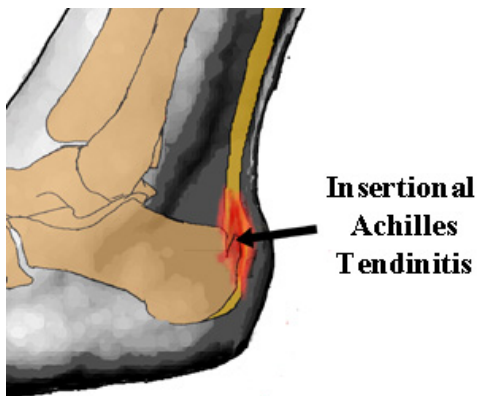


Achilles Tendinopathy:

This condition is usually categorised as either insertional or non-insertional depending on the location of the problem:

Insertional tendinopathy affects the tendon as it joins the heel bone at the back of the heel as shown in the diagram below left:

The affected area can become hot and swollen and look similar to the picture below on the right:



The other type of tendinopathy usually affects the mid tendon which can become swollen and thickened and look similar to the picture below on the left:

